Laparoscopic pudendal nerve decompression and transposition combined with omental flap protection of the nerve (Istanbul technique): technical description and feasibility analysis

Tibet Erdogru, Egemen Avci & Murat Akand

Surgical Endoscopy
And Other Interventional Techniques
Official Journal of the Society of American Gastrointestinal and Endoscopic Surgeons (SAGES) and European Association for Endoscopic Surgery (EAES)

ISSN 0930-2794
Volume 28
Number 3

Surg Endosc (2014) 28:925-932
DOI 10.1007/s00464-013-3248-1

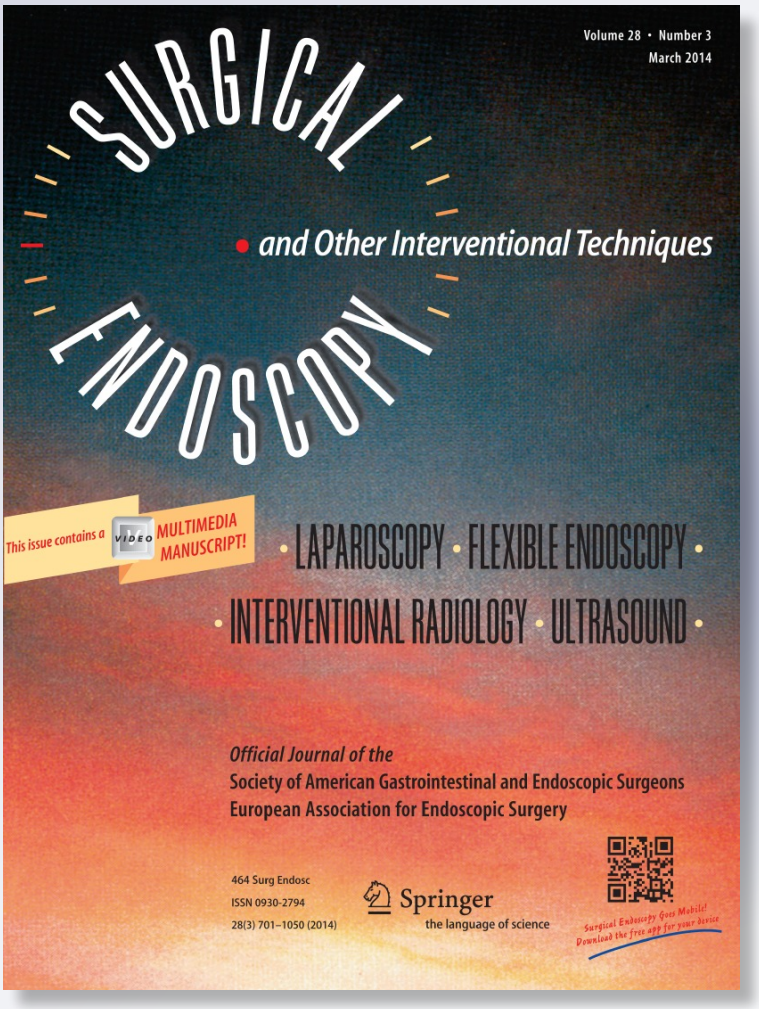

Springer

Your article is protected by copyright and all rights are held exclusively by Springer Science +Business Media New York. This e-offprint is for personal use only and shall not be self-archived in electronic repositories. If you wish to self-archive your article, please use the accepted manuscript version for posting on your own website. You may further deposit the accepted manuscript version in any repository, provided it is only made publicly available 12 months after official publication or later and provided acknowledgement is given to the original source of publication and a link is inserted to the published article on Springer's website. The link must be accompanied by the following text: "The final publication is available at link.springer.com”.

Springer

Author's personal copy

Surg Endosc (2014) 28:925–932
DOI 10.1007/s00464-013-3248-1

Laparoscopic pudendal nerve decompression and transposition combined with omental flap protection of the nerve (Istanbul technique): technical description and feasibility analysis

Tibet Erdogru · Egemen Avci · Murat Akand

Received: 12 April 2013 / Accepted: 4 October 2013 / Published online: 23 October 2013
© Springer Science+Business Media New York 2013

Abstract

Background We aimed in this study to investigate the efficacy of laparoscopic pudendal nerve decompression and transposition (LaPNDT) in the treatment of chronic pelvic pain due to pudendal neuralgia. Pudendal nerve entrapment (PNE) between the sacrospinous and sacrotuberous ligaments is the most frequent etiology. We describe the technical details, feasibility, and advantages of a laparoscopic approach in patients with PNE.

Methods Consecutive patients ($n = 27$) with a diagnosis of PNE underwent LaPNDT with omental flap protection in an effort to prevent re-fibrosis around the nerve in the long term. The degree of pain and pain impact were evaluated pre- and postoperatively using the visual analog pain scale (VAS) and the Impact of Symptoms and Quality of Life.

Results The mean (±standard deviation [SD]) follow-up of the 27 patients was 6.8 ± 4.2 months; 16 of the 27 were followed-up for more than 6 months. The mean (SD) operation time was 199.4 ± 36.1 (155–300) min, and the mean estimated blood loss was 39.7 ml. All patients were ambulated on the first postoperative day, and the mean (SD) hospitalization time was 2.1 ± 1.0 (1–6) days. The mean VAS scores of 27, 23, 16, and 6 patients were 1.5, 1.4, 1.6, and 2.0, postoperatively, at the first, third, sixth, and twelfth months ($p < 0.0001$). A more than reduction in VAS score (>80 %) was achieved in 13 of the 16 patients (81.2 %) who were followed-up for more than 6 months.

Conclusions LaPNDT seems a feasible surgical modality for cautiously selected patients with PNE. In addition, using an omental flap for protection of the nerve is one of the most important technical advantages of laparoscopy. As a minimally invasive surgery, the laparoscopic approach can be technically feasible, with its promising preliminary results in the treatment of PNE. With further analysis, in the future it may open new frontiers for pudendal nerve neuromodulation as a new treatment modality in some intractable functional problems of the genitourinary tract.

Keywords Urology · Laparoscopy · Pain · Neurourology · Pudendal nerve

T. Erdogru (✉) · E. Avci
Department of Urology, Minimally Invasive and Robotic Surgery Center, Memorial Istanbul Atasehir Hospital, Vedat Gunyol Street, Nr:30-31, Istanbul, Turkey
e-mail: dr@tibeterdogru.com

T. Erdogru · M. Akand
Department of Urology, Minimally Invasive Center, Memorial Antalya Hospital, Antalya, Turkey

Chronic pelvic pain (CPP) is a challenging entity that has devastating consequences for the quality of life (QoL) of patients. Pudendal neuralgia (PN) is one of the important and most underdiagnosed causes of chronic, intractable, disabling pelvic pain in both men and women. The pudendal nerve is composed of both motor and sensory fibers, deriving from sacral roots S2, S3, and S4 and innervating the anogenital area and pelvic muscles (bulbospongiosus and ischiocavernosus). Caudally, the pudendal nerve enters a small passageway ('clamp') between the sacrospinous ligament (SSL) and the sacrotuberous ligament (STL), close to the ischial spine, before entering Alcock's canal, formed by a division of the obturator muscle aponeurosis [1, 2].

The most frequent etiology of PN is pudendal nerve entrapment (PNE) between the SSL and the STL at the level of the ischial spine and entrance to Alcock's canal [3]. While the pathophysiology is similar to carpal tunnel syndrome, the location of the pudendal nerve is the main problem, not only for patient selection but also for reaching the nerve located in the deep pelvis.

Author's personal copy

Laparoscopic surgery in pelvic peripheral neural structures has been used for pelvic pathologies [4]. Recently, cadaveric studies have shown the feasibility of a laparoscopic approach to decompress the pudendal nerve by cutting the SSL [5]. However, the feasibility of laparoscopic pudendal nerve surgery in clinical practice has not been published in the literature. We propose laparoscopic pudendal nerve decompression and transposition with omental flap wrapping of the pudendal nerve as a new surgical treatment option for PNE. In this study, we describe the technical details and clinical feasibility, in addition to the advantages, of the laparoscopic approach in patients with intractable CPP due to PNE.

Patient and methods

Patients with PNE ($n = 27$) were diagnosed using our diagnostic protocol, required clinical history (chronic, disabling, intractable neuropathic pain in the distribution of the pudendal nerve aggravated by sitting), physical examination, and abnormal neurophysiology testing (any pudendal electromyography [EMG] abnormality), pelvic magnetic resonance imaging (MRI), or response to the anesthetic portion of the pudendal nerve block. Visual analog pain scale (VAS) ratings of patients were recorded as current, baseline (VAS-B) and worst (during pain attacks) (VAS-W). Before and shortly after the diagnostic block, patients assessed their pain using a VAS of 0–10 for pain while sitting on a hard bench. A more than 50 % decrease in pain level was accepted as a positive response.

Our basic criteria for performing laparoscopic surgery were as follows: (A) resistance of at least one of the three following symptoms to conservative treatments: (i) anogenital pain or perineodynia (on at least one side), (ii) painful lower urinary tract symptoms, and (iii) dyspareunia or painful erection–ejaculation, and (B) association of at least two of the following criteria: (i) increased anal or perineal pudendal nerve motor latency test (PNMLT), (ii) pathological EMG of the anal sphincter or bulbocavernosus muscles, (iii) painful Alcock's canal and SSL on rectal or vaginal examination (on at least one side), (iv) decrease in pain with pudendal nerve block, and (v) painful skin-rolling test (Kibler fold test).

Surgical technique

Laparoscopic pudendal nerve decompression and transposition combined with protection of the nerve using omental flap (Istanbul technique)

In our transperitoneal laparoscopic dissection technique, we use a 30° telescope and five trocars (one 12 mm optic trocar, placed using infraumbilical incision with Hasson technique, one 10 mm trocar, and three 5 mm trocars) with positioning similar to that used in our uro-oncologic pelvic surgeries as previously described [6] (Fig. 1). In female patients, two additional technical supports are necessary: an intrauterine manipulator, for retraction of the uterus to the side contralateral to the surgical side, and a straight needle, passing from outside the body, under the ovaries and tubes, and outside the body again to lift these structures.

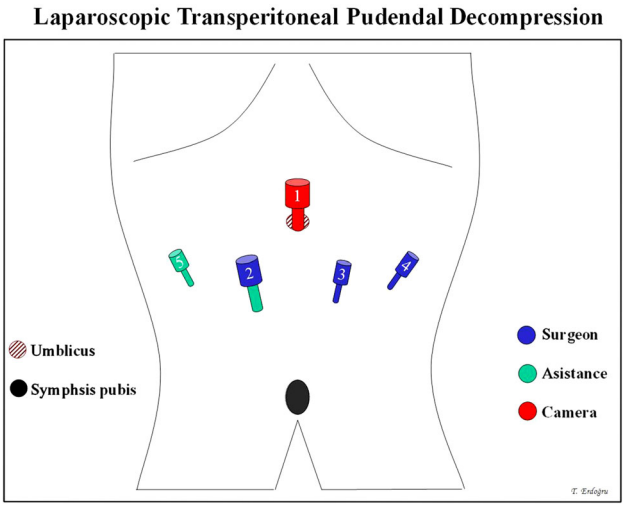

Fig. 1 Locations of the trocars as assistance, surgeon, and camera of the laparoscopic pudendal nerve decompression and transposition

The external iliac vein is identified, and the peritoneum is incised between the ureter and external iliac vein. Blunt dissection is used to create a peritoneal window medial to the obturator nerve. The inner border of the peritoneal layer is then retracted medially to allow visualization of the internal iliac artery, vein and arcus tendineus fasciae pelvis. For better visualization, division of the medial umbilical ligament as the first branch of the internal iliac artery and partial internal iliac lymph dissection might be required; all fatty tissue has to be removed over the arcus tendineus fasciae. The arcus tendinous fascia of the pelvis is incised and retracted medially to fully expose the lateral border of both the internal iliac artery and the vein. These vessels might then be mobilized and traced distally, to the posterior border of the ischiococcygeus muscle, if there is a narrow space such as in an obese patient. Following these structures distally allows exposure of the SSL and the lateral deep pelvic topographic anatomy from an internal perspective (Fig. 2A).

As demonstrated in detail in a previous cadaveric study [5], the dense and thickening SSL is identified and bluntly dissected from the pudendal artery, vein, and nerve. Using 5 mm scissors, the SSL is then completely divided, with retraction and protection of the pudendal nerve with an

Author's personal copy

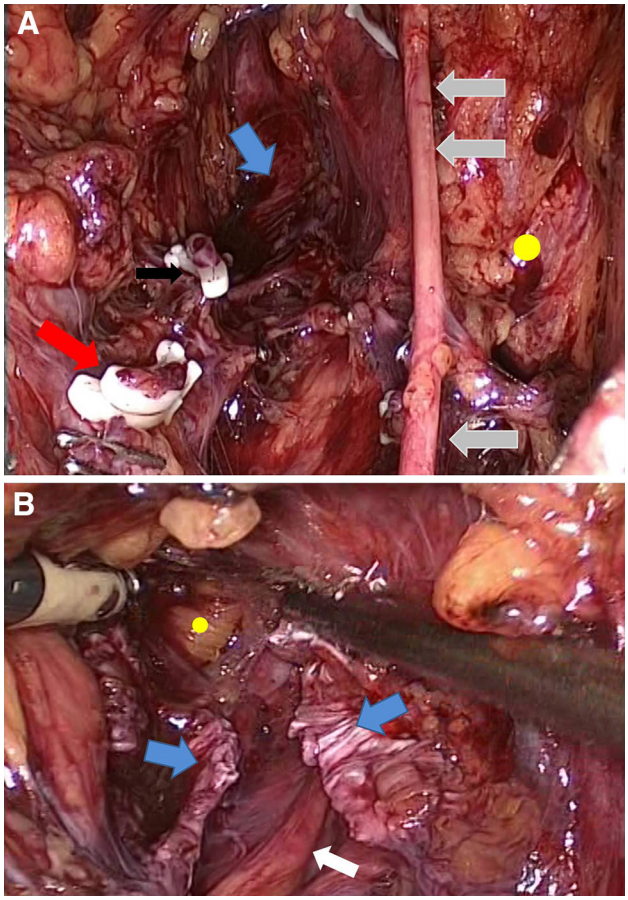

Fig. 2 **A** Exposure of the sacrospinous ligament (SSL) from an internal perspective and the lateral deep pelvic topographic anatomy. *Blue arrow* the right SSL. *Black arrow* divided right obturator vein. *Red arrow* divided medial umbilical ligament. *Gray arrows* right obturator nerve. **B** With division of SSL, pudendal nerve clearly identified beneath the ligament and the fatty tissue in front of Alcock's canal entrance. *Blue arrows* divided right SSL. *White arrow* the right pudendal nerve. *Yellow dot* the fatty tissue in front of Alcock's canal entrance

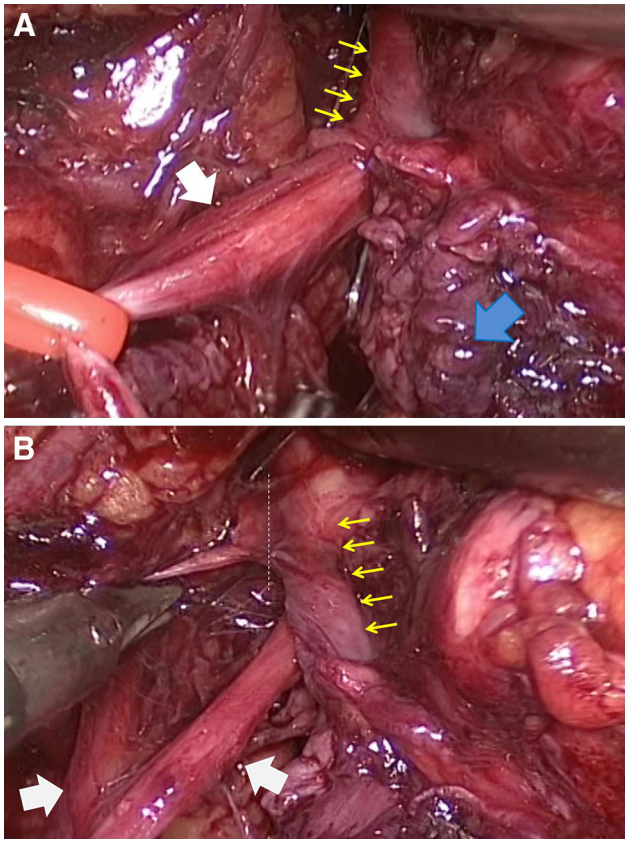

Fig. 3 **A** The entrance of the right pudendal nerve into Alcock's canal with the view of medial side of the aponeurosis of internal obturator muscle as the inside wall of Alcock's canal. *White arrow* right pudendal nerve. *Blue arrow* incised right sacrospinous ligament (SSL). *Yellow arrows* inside wall of Alcock's canal as the aponeurosis of internal obturator muscle. **B** After incision of proximal part of Alcock's canal, the right deep perineal branch of the pudendal nerve has been identified. *White arrow* right pudendal nerve. *Yellow arrows* inside wall of Alcock's canal as the aponeurosis of internal obturator muscle

endo-dissector (Fig. 2B). Dissection of the pudendal nerve continues to the proximal entrance to Alcock's canal, with splitting of the inner side of the levator ani muscles to reach the fatty tissue in front of the canal entrance and inner part of the aponeurosis of the internal obturator muscle (Fig. 3A). From the proximal side of the canal, the upper wall is opened with incision of the aponeurosis, which forms the upper wall of the canal (Fig. 3B). After the pudendal nerve is decompressed and released, it is transposed outside the area between the SSL and STL (Fig. 4A for the right side and Fig. 4B for the left side). As the last and most important part of the laparoscopic surgery, the omental flap is transposed to the deep pelvic region. If the surgery has been performed bilaterally, the omental flap should be prepared in a 'V' shape to reach both sides. The decompressed nerve is then wrapped by the omental flap to protect the nerve against scar tissue development around it, resulting in re-entrapment (Fig. 5). The omental flap should be fixed to the lower part of the arcus tendineus fasciae using 2/0 Vicryl™ suture, and both edges of the flap should be closed using the same continuous suture while visualizing the nerve. As the last step of the surgery, the incised peritoneal layers are reapproximated using 2/0 Vicryl™ continuous suturing without compression of the omental flap.

Outcome measures

At the time of diagnosis, assessments of pain were made using VAS scores and questions from the Impact of Symptoms and Quality of Life (IQoL) index of the National Institutes of Health Chronic Prostatitis Symptom Index (NIH-CPSI) that relate to function and QoL [7]

Author's personal copy

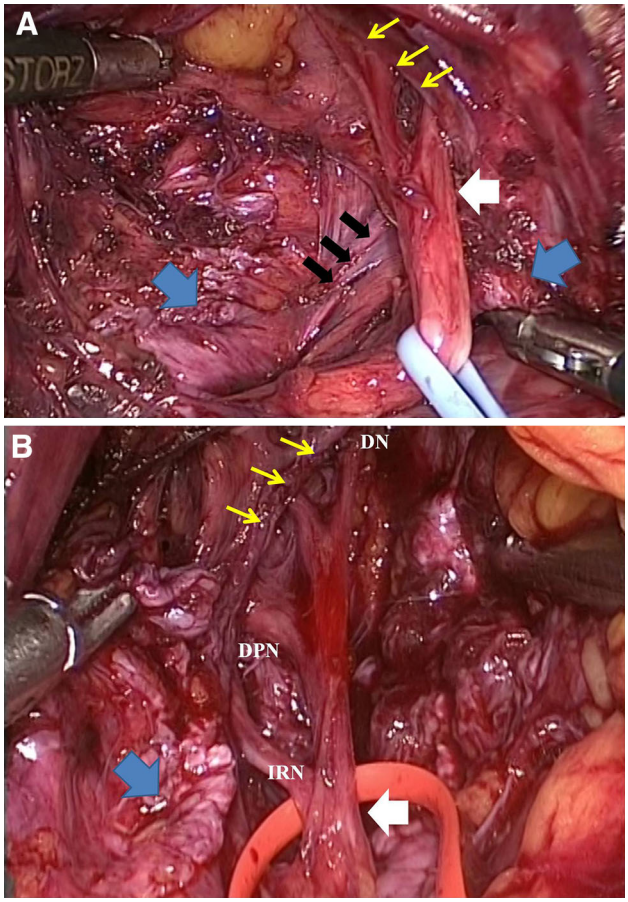

Fig. 4 **A** Right decompressed pudendal nerve after incising sacrospinous ligament (SSL) and inner side of aponeurosis of internal obturator muscle. *White arrows* right pudendal nerve and its distal branches. *Blue arrows* incised right SSL. *Black arrows* processus falciformis of the sacrotuberous ligament (STL). *Yellow arrows* incised medial side of Alcock's canal. **B** Left decompressed pudendal nerve and its distal branches is transposed to the medial side of the incised SSL. *White arrow* left pudendal nerve and its distal branches. *Blue arrow* incised left SSL. *Yellow arrows* incised inner side of the aponeurosis of internal obturator muscle as the inner wall of Alcock's canal. *DN* clitoral nerve, *DPN* deep perineal nerve, *IRN* inferior rectal nerve

(Tables 1, 2). These assessments were repeated at 1, 3, 6, and 12 months or longer following surgery, at which time patients also completed a post-surgical questionnaire (Tables 3, 4). The answers to these questions were converted to a numeric score to better quantitate results as described previously [7].

Statistical methods

First, the efficacy of the surgery with respect to symptoms and clinical signs was studied by means of descriptive statistics. The mean values of the VAS and numeric scores of the IQoL index of the NIH-CPSI before versus after surgery were compared at each follow-up period. A statistical comparison between pre- and postoperative values for each evaluation period was conducted. Statistical analysis of differences was performed using χ [2] testing for categorical variables and *t*-tests and one-way analysis of variance combined with Newman–Keuls multiple comparison tests for continuous variables.

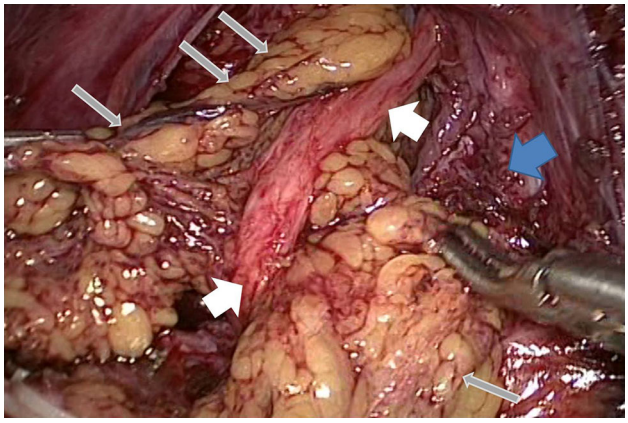

Fig. 5 Right decompressed and transposed pudendal nerve and its branches have been covered and protected using an omental flap for prevention against re-entrapment due to perineural fibrosis. *White arrows* right pudendal nerve. *Gray arrows* omental flap for wrapping each branch and main pudendal nerve. *Blue arrow* incised right sacrospinous ligament

Table 1 Pre-operative questionnaire

Pre-operative	
IQoL Q1. How often have you had pain or discomfort in the area over the last month?	
(a) Never	(Score: 4)
(b) Rarely	(Score: 3.3)
(c) Sometimes	(Score: 2.66)
(d) Often	(Score: 2)
(e) Usually	(Score: 1.3)
(f) Always	(Score: 0.66)
IQoL Q2. How much have your symptoms kept you from doing the kinds of things you over the last month?	
(a) None	(Score: 4)
(b) Only a little	(Score: 3)
(c) Some	(Score: 2)
(d) A lot	(Score: 1)
IQoL Q3. If you were to spend the rest of your life with your symptoms just the way they have been, how would you feel?	
(a) Delighted	(Score: 4)
(b) Pleased	(Score: 3.5)
(c) Mostly satisfied	(Score: 3)
(d) Mixed	(Score: 2.5)
(e) Mostly dissatisfied	(Score: 2)
(f) Unhappy	(Score: 1.5)
(g) Terrible	(Score: 1)

Author's personal copy

Table 2 Pre-operative visual analog scale: which number best describes your average pain or discomfort

☐	☐	☐	☐	☐	☐	☐	☐	☐	☐	☐
0	1	2	3	4	5	6	7	8	9	10

Table 3 Postoperative questionnaire

Postoperative	
i. When was your surgery?	
ii. From month to month following surgery, has your pain been decreasing? If so, what is your overall percent improvement? …….%	
IQoL Q1. How often have you had pain or discomfort in any of the previously afflicted areas since surgery?	
(a) Never	(Score: 4)
(b) Rarely	(Score: 3.3)
(c) Sometimes	(Score: 2.66)
(d) Often	(Score: 2)
(e) Usually	(Score: 1.3)
(f) Always	(Score: 0.66)
IQoL Q2. How much have your symptoms kept you from doing the kinds of things you would usually do, since surgery?	
(a) None	(Score: 4)
(b) Only a little	(Score: 3)
(c) Some	(Score: 2)
(d) A lot	(Score: 1)
IQoL Q3. If you were to spend the rest of your life with your symptoms just the way they have been since surgery, how would you feel?	
(a) Delighted	(Score: 4)
(b) Pleased	(Score: 3.5)
(c) Mostly satisfied	(Score: 3)
(d) Mixed	(Score: 2.5)
(e) Mostly dissatisfied	(Score: 2)
(f) Unhappy	(Score: 1.5)
(g) Terrible	(Score: 1)
IQoL Q4. How much do you think about your symptoms since surgery?	
(a) None	(Score: 4)
(b) Only a little	(Score: 3)
(c) Some	(Score: 2)
(d) A lot	(Score: 1)

Results

The demographic features and operative results of the 27 patients (24 female, 3 male) are summarized in Table 5. These patients presented with a history of progressive, chronic, intractable neuropathic pain localized in the anogenital region. Other baseline symptoms included urinary hesitancy, frequency, and urgency symptoms (64 %), constipation (45 %), including painful bowel movements, and sexual dysfunction due to dyspareunia or painful ejaculation (70 %). Most patients were severely disabled by their pain, with symptoms affecting QoL and limiting the patient's ability to engage in normal daily activities. Based on the IQoL index, 82 % responded that they would be unhappy or feel terrible if they "… were to spend the rest of [their] life with symptoms exactly as they have been," and 72 % responded that their symptoms "… kept [them] from doing the kind of things [they] would usually do over the last month." In all patients who underwent surgery, conservative treatment had failed; two patients underwent repeat operation due to recurrence 6 months after laparoscopic pudendal nerve decompression, which was performed without omental flap wrapping of the nerve for protection.

Table 4 Postoperative visual analog scale: which number best describes your average pain or discomfort on the days you had it since surgery?

☐	☐	☐	☐	☐	☐	☐	☐	☐	☐	☐
0	1	2	3	4	5	6	7	8	9	10

The mean (±standard deviation [SD]) operation time was 199.4 ± 36.1 (155–300) minutes, and the mean estimated blood loss was 39.7 ml. All patients were ambulated on the first postoperative day, and the mean (±SD) hospitalization time was 2.1 ± 1.0 (1–6) days.

The mean (±SD) follow-up of 27 patients was 6.8 ± 4.2 (1–15) months; 16 were followed-up for more than 6 months, and six of them were followed-up for more than 12 months.

The preoperative mean pain scores during daily routines as VAS-B (5.6 ± 1.4; 2–8) and during pain attacks as VAS-W (8.4 ± 1.1; 6–10) were compared with postoperative VAS levels (Table 5). The mean VAS scores of 23, 16, and 6 patients were 1.4, 1.6, and 2.0, postoperatively, at the third, sixth, and twelfth months. The reduction in VAS values was statistically significant in all patients ($p < 0.0001$). A more than 80 % reduction in VAS was achieved in 19 of 23 patients (82 %) followed-up for more than 3 months, while this rate was 81 % in the 16 patients followed-up for more than 6 months (with the mean follow-up of 9.6 months). In the 16 patients followed-up for more than 6 months, the mean scores of the questions of the IQoL index significantly increased in the postoperative period (Table 6).

Surgical morbidity was observed in six patients (19 %), including Clavien classification Grade I in two patients (as numbness in a small patch of the PN area) and Clavien classification Grade II in four patients (as transient

Author's personal copy

Table 5 Patient demographics, operative results, and pre- and postoperative VAS and IQoL scores

Patients age (year)			43.9 ± 8.6 (25–58)		
Duration of the PNE (year)			4.3 ± 3.4 (1–13)		
Operation time (minute)			206.5 ± 46.3 (125–325)		
Hospitalization (day)			2.1 ± 1.0 (1–6)		
Oral intake (day)			1.1 ± 0.3 (1–2)		
Follow-up (month)			6.8 ± 4.2 (1–15)		
VAS results					
VAS-B ($n = 27$)	VAS-C ($n = 27$)	VAS-1 ($n = 27$)	VAS-3 ($n = 23$)	VAS-6 ($n = 16$)	VAS-12 ($n = 6$)
5.6 ± 1.4 (3–8)	8.4 ± 1.1 (7–10)	1.5 ± 1.6 (0–6)	1.4 ± 1.8 (0–6)	1.6 ± 2.1 (0–0)	2.0 ± 1.5 (0–4)

IQol impact of symptoms and quality of life index, *PNE* pudendal nerve entrapment, *VAS* visual analog scale

Table 6 IQoL results

	Preoperative	3rd month	6th month	12th month
IQoL Q1	1.1 ± 0.5	3.2 ± 1.0	3.2 ± 1.2	3.0 ± 1.4
IQoL Q2	1.3 ± 0.4	3.0 ± 1.0	3.1 ± 1.3	3.0 ± 1.4
IQoL Q3	1.4 ± 0.4	3.2 ± 1.0	3.1 ± 1.0	2.8 ± 1.1

IQol impact of symptoms and quality of life index

dysfunction in adduction due to obturator nerve retraction ($n = 1$), transient urinary retention ($n = 1$) treated with alpha-blockers, deep venous thrombosis resulting in tibial nerve damage ($n = 1$), and peroneal nerve paralysis ($n = 1$) due to lithotomy position during surgery, which was conservatively treated.

Discussion

CPP syndrome is a complex problem for the multiple specialists to whom affected patients present for healthcare. Generally, both females and males with CPP are referred from one specialist to another, and a variety of different ineffective treatments are attempted. PNE should be considered for patients with neuropathic pain in the pudendal nerve distribution (male: penis, testicles, perineum, rectum; female: labia, clitoris, perineum, rectum) that worsens with sitting. The pain may or may not be associated with bladder or sexual (especially orgasmic) dysfunction. The ideal management for CPP related to PN has not been defined. A combination of medication, such as non-steroidal anti-inflammatory drugs (NSAIDs), tricyclic antidepressants, anticonvulsants, and narcotics, are used, but they have shown poor results. Pudendal nerve blocks under computed tomographic (CT) or fluoroscopic guidance have been described previously. However, only short-term positive responses are available, varying from 62 to 87 % [8, 9].

Surgical decompression of the nerve may be an alternative in selected patients when there is temporary or partial improvement after nerve blockade and if compression of the nerve is still suspected. There are three different surgical approaches: transperineal, transgluteal, and via the ischiorectal fossa. The results on pain reduction seem to be similar between the different approaches, ranging from 50 to 86 % [10–12], but only one prospective controlled study is available demonstrating a superior impact of pudendal decompression when compared with the control group, with a significant decrease in pelvic pain during the long-term follow-up [12]. The transperineal approach was first described by Shafik et al. [11] in 1991. Initially, this procedure only dilated Alcock's canal. The pudendal nerve was released from the surrounding tissue and laid free in the ischiorectal fossa. Lying free and no longer forming the loop when entering the canal provides the nerve with its potential length, which prevents it from being stretched during levator activity. However, this technique also has some disadvantages, being a blunt procedure and providing limited vision. Beco et al. [10] demonstrated that bilateral transperineal decompression can be an effective treatment for perineal pain and also urinary and fecal incontinence. The main disadvantages of the transperineal approach are difficult access due to abundance of fatty tissue, the depth of the region, and proximity of numerous veins. The transgluteal approach described by Robert et al. [12] seems to be more practical because it allows freeing the entire trunk through a single approach. The gluteal incision is made in the axis of the fibers of the gluteus maximus muscle on either side, with a transverse limb passing over the coccyx and situated at the level of the ischial spine. For all open techniques, in addition to their invasiveness and other disadvantages, one of the most important limiting and precarious factors affecting their long-term success is that there is no possibility to protect the nerve against re-fibrosis and possible re-entrapment [12].

One of the first steps in CPP management is to determine the etiology to treat, and laparoscopy has become the standard for diagnosis and treatment in many surgical fields. Because of the high-quality vision and magnification

Author's personal copy

it affords and the possibility of blood-free dissection, even in the deep pelvis, laparoscopic surgery is becoming one of the most useful and important instruments in learning about and operating on the deep pelvic anatomy. The combination of a high level of knowledge of the pelvic neuroanatomy and the laparoscopic dissection technique in the deep pelvis, with its advantages of magnification and high-definition visualization, allows us a very gentle dissection of the pelvic nerves using laparoscopic mini-instruments. Due to advances in endoscopic video systems, laparoscopic microsurgical instruments and introduction of intraoperative electrostimulation of the pelvic nerves, laparoscopy should become the preferred method for the etiologic clarification of CPP due to pelvic neuralgia and treatment with classical neurosurgical procedures such as decompression, neurolysis, and implantation of electrodes for neuromodulation. In addition, the laparoscopic technique has another important advantage in that, with omental flap protection, it prevents re-fibrosis around the nerve in the long-term.

In our prospectively documented patient group, not only pain scores but also QoL scores were significantly improved in the early and long-term postoperative period. Only three patients of 16 (25 %) reported a less than 80 % reduction in the pain scale, accepted as no improvement, or recurrence in pelvic pain after the sixth month. Despite fibrotic reaction around the nerve during the postoperative period, omental flap protection during the laparoscopic transperitoneal approach, described for the first time in this report, might be an additional advantage in the long-term follow-up.

In our series, all complications were classified as Clavien I or II. However, potential complications could include major vascular (internal iliac vein and artery) injury resulting in bleeding due to the close and limited area in the deep pelvis or accidental neural damage, especially in anatomic variants. Therefore, advanced pelvic laparoscopic surgical experience is required in order to diminish the risk for potential major complications.

PN seems to exist as a clinical syndrome rather than a specific diagnosis. There is no evidence to support equating the presence of this syndrome with a diagnosis of PNE, although that may be one etiological condition [13]. Each case needs careful assessment on its own merits, and treatment needs to be individualized. For surgical consideration, the laparoscopic approach has important advantages and opens new frontiers in CPP syndrome. Based on previous and our own experience, laparoscopic exposure of all somatic and autonomous pelvic nerves has become feasible, not due to new findings in the pelvic neuroanatomy, but due to the introduction of laparoscopic surgery into the field of deep pelvic surgery. Laparoscopic magnification allows the surgeon a microscopical vision of these very small nerves even in the depth of the pelvis, or in other areas that are difficult to access. The second important aspect making this dissection feasible is that laparoscopy obliges the surgeon operating in the deep pelvic space to have better knowledge of the pelvic anatomy.

In conclusion, PNE is a largely unknown and unrecognized condition in CPP. As a minimally invasive surgery, the laparoscopic approach can be technically feasible with its surgical advantages and promising preliminary results in the treatment of properly selected patients with CPP syndrome due to PNE using the 'Nantes Criteria' [14]. In addition, the laparoscopic approach might open new frontiers for sacral and pudendal nerve neuromodulation with the correct placement and fixation of electrodes over the nerves with its technical feasibility.

Acknowledgments The authors thank Professor Dr. Vito Pansodoro, Professor Dr. Vincenzo Di Santo, and Associate Professor Dr. Evangelos Liatsikos for their kind support and technical ideas in developing this technique.

Disclosures Tibet Erdogru, Egemen Avci, and Murat Akand declare no conflicts of interest.

References

1. Lazarou G, Grigorescu BA, Olson TR, Downie SA, Powers K, Mikhail MS (2008) Anatomic variations of the pelvic floor nerves adjacent to the sacrospinous ligament: a female cadaver study. Int Urogynecol J 19:649–654
2. Insola A, Granata G, Padua L (2010) Alcock canal syndrome due to obturator internus fibrosis. Muscle Nerve 42:431–432
3. Loukas M, Louis RG, Hallner B, Gupta AA, White D (2006) Anatomical and surgical considerations of the sacrotuberous ligament and its relevance in pudendal nerve entrapment syndrome. Surg Radiol Anat 28:163–169
4. Possover M (2009) Laparoscopic management of endopelvic etiologies of pudendal pain in 134 consecutive patients. J Urol 181:1732–1736
5. Loukas M, Louis RG, Tubbs S, Wartmann C, Colbom GL (2008) Intra-abdominal laparoscopic pudendal canal decompression: a feasibility study. Surg Endosc 22:1525–1532
6. Erdogru T, Teber D, Frede T, Marrero R, Hammady A, Seeman O, Rassweiler J (2004) Comparison of transperitoneal and extraperitoneal laparoscopic radical prostatectomy using match-pair analysis. Eur Urol 46:312–319
7. Popeney C, Ansell V, Renney K (2007) Pudendal entrapment as an etiology of chronic perineal pain: diagnosis and treatment. Neurourol Urodyn 26:820–827
8. Choi SS, Lee PB, Kim YC, Kim HJ, Lee SC (2006) C-arm-guided pudendal nerve block: a new technique. Int J Clin Pract 60:553–556
9. Filler A (2009) Minimal access nerve surgery and interventional magnetic resonance imaging. Neurosurgery 65:212–221
10. Beco J, Climov D, Bex M (2004) Pudendal nerve decompression in perineology: a case series. BMC Surg 30:4–15
11. Shafik A, El Sibai O, Shafik IA, Shafik AA (2007) Role of sacral ligament clamp in the pudendal neuropathy (pudendal canal syndrome): results of clamp release. Int Surg 92:54–59

Author's personal copy

12. Robert R, Labat JJ, Bensignor M, Glemain P, Deschamps C, Raoul S, Hamel O (2005) Decompression and transposition of the pudendal nerve in pudendal neuralgia: a randomized controlled trial and long-term evaluation. Eur Urol 47:403–408
13. Santos FI, Salinas J, Zarza D, Sancha FG, Almagro A (2010) Update on pudendal nerve entrapment syndrome: an approach anatomic-surgical, diagnostic and therapeutic. Actas Urol Esp 34:500–509
14. Labat JJ, Riant T, Robert R, Amarenco G, Lefaucheur JP, Rigaud J (2008) Diagnostic criteria for pudendal neuralgia by pudendal nerve entrapment (Nantes Criteria). Neurourol Urodyn 27:306–310